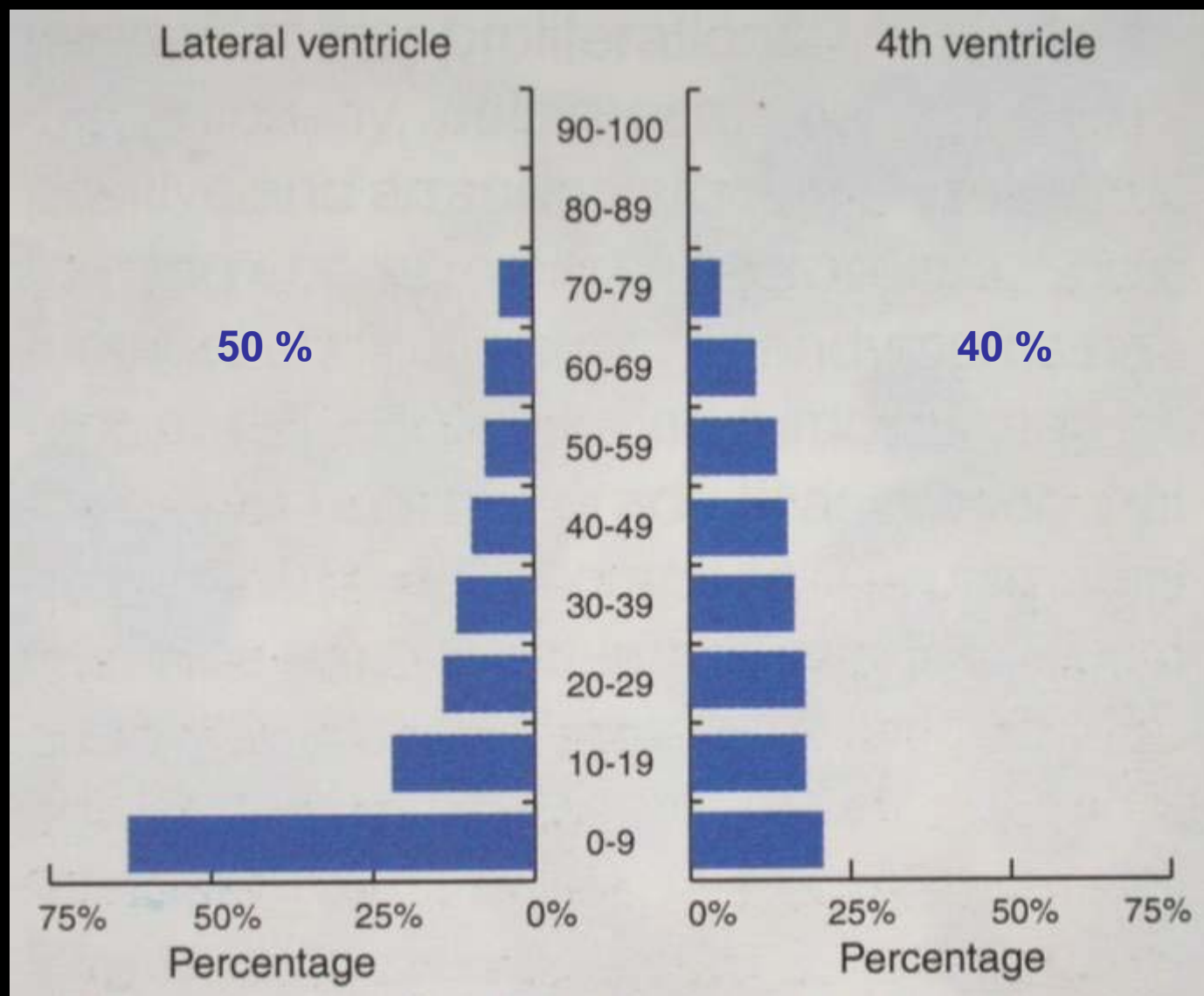
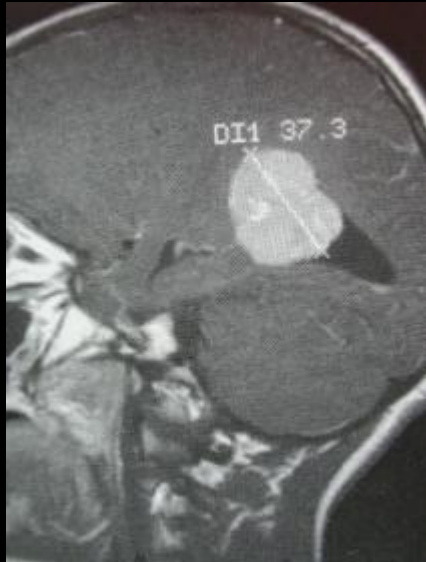


# Tumeurs du plexus choroïde

# Tumeurs du plexus choroïde

- Incidence:
  - 0.5 % des tumeurs cérébrales
  - HDF: 3 cas / 15 ans
    - » (# 470 TC / 8 ans)
- ☺ / Ж : 5 / 1
- Incidence annuelle: 0.3 / M

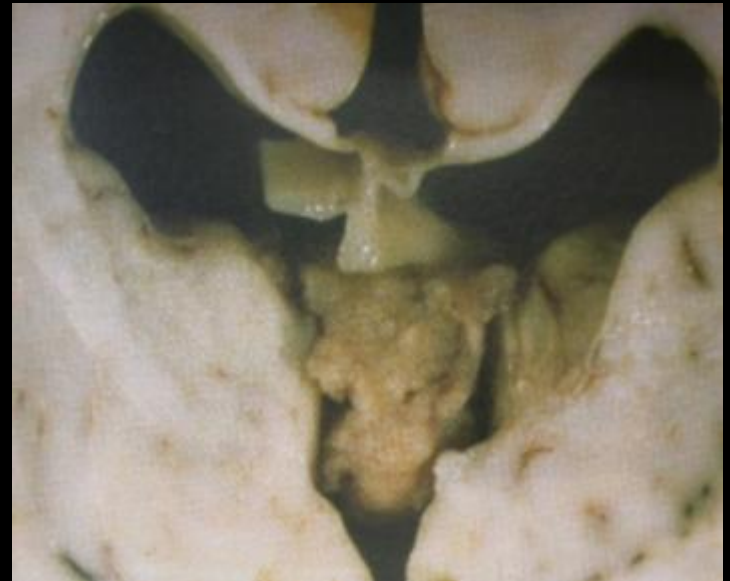
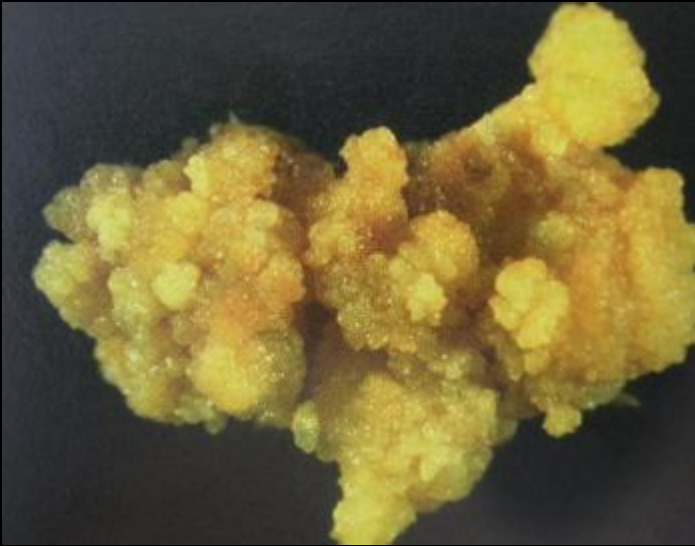


Tumeurs du plexus choroïde: Age vs Localisation.

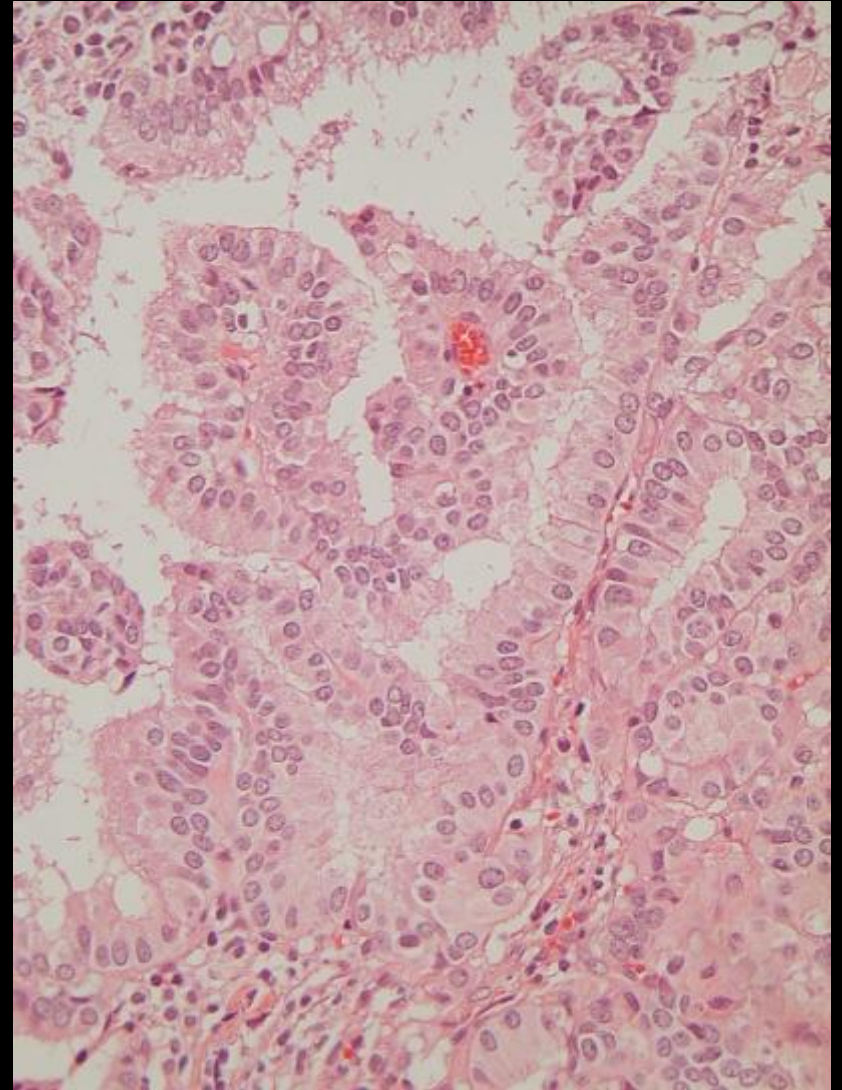
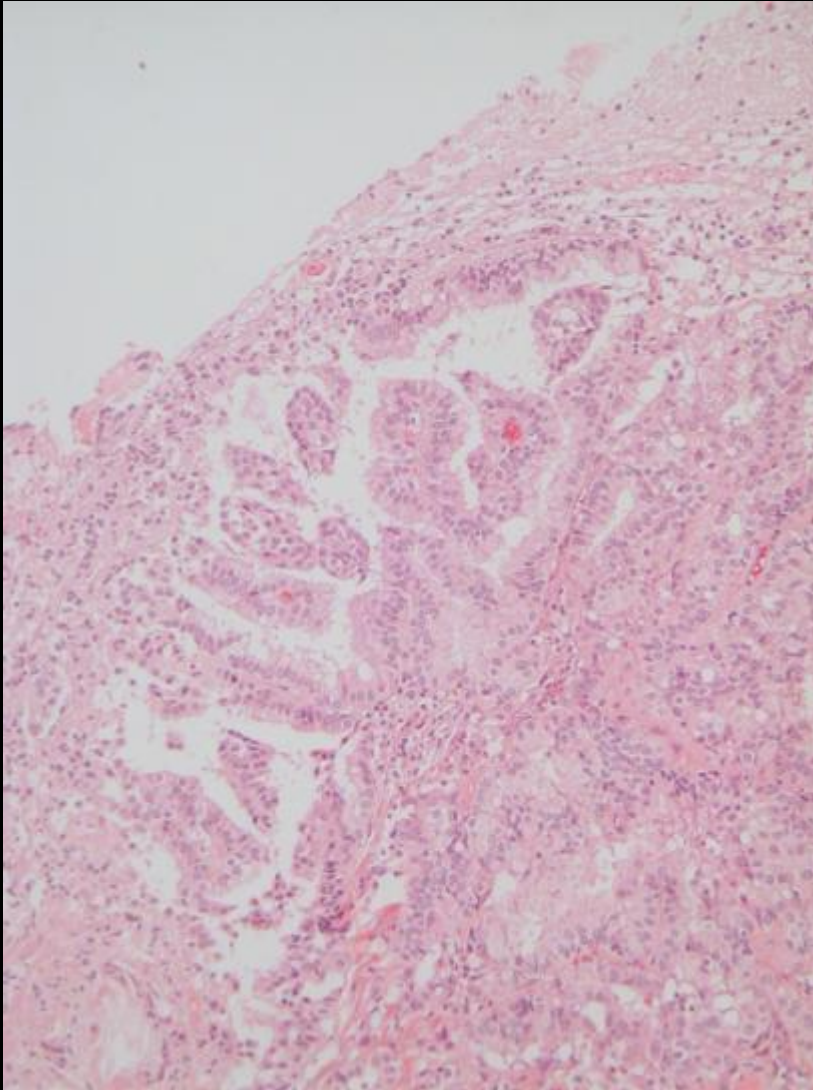
(Compilation de cas publiés)

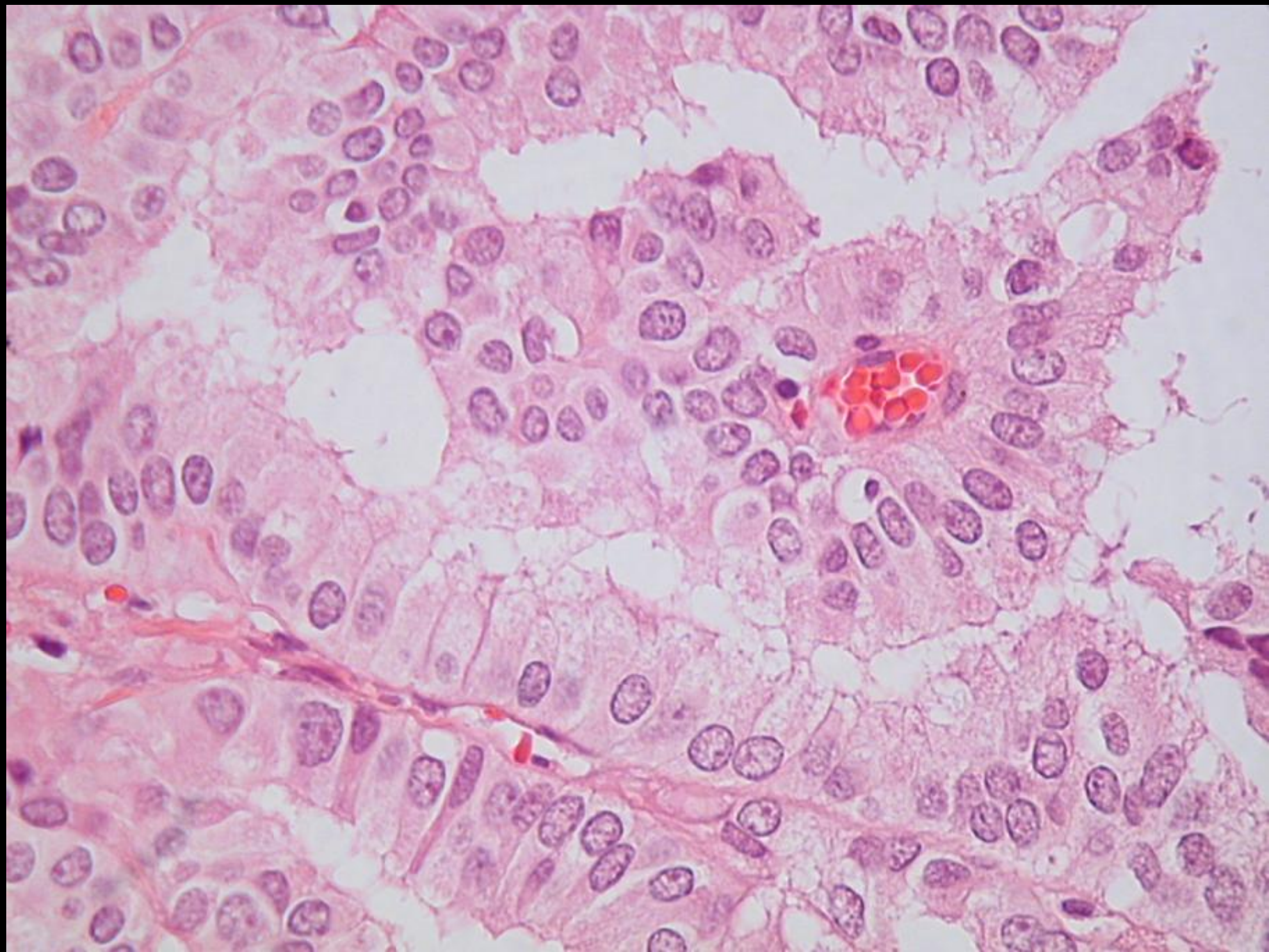
Ref. Pathology and Genetics, Tumours of the Nervous System, WHO 1997

# Tumeurs du plexus choroïde: Macroscopie

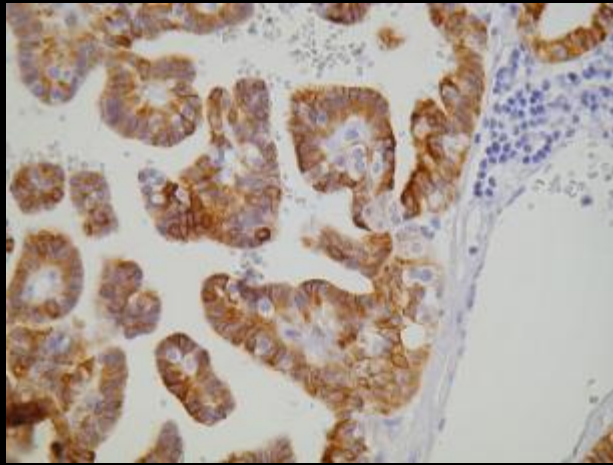


# Tumeurs du plexus choroïde: Microscopie

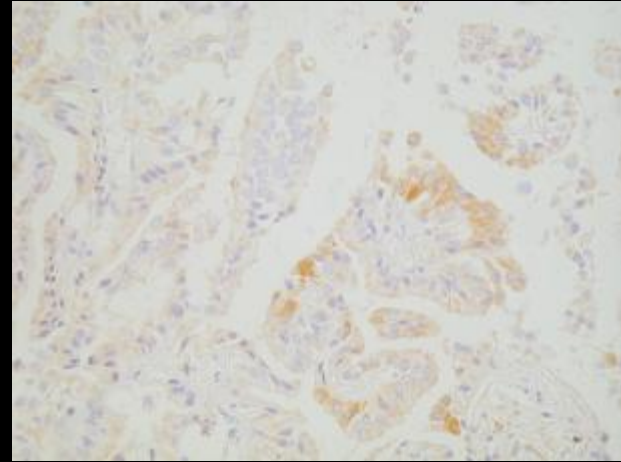




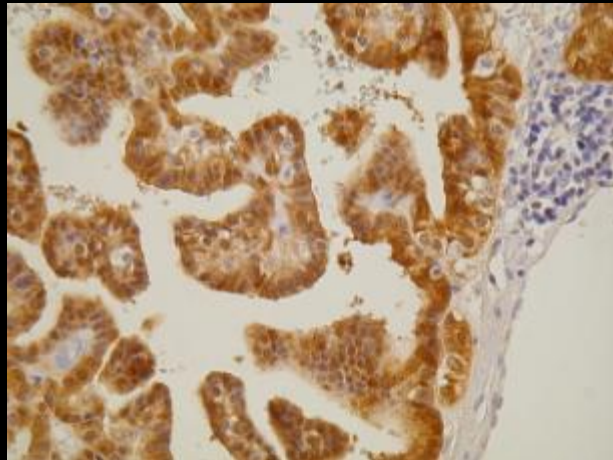
# Tumeurs du plexus choroïde: Immunohistochimie



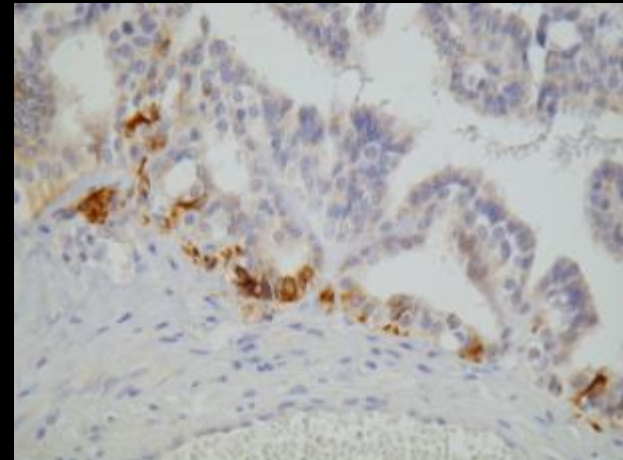
Cytokeratines



EMA



S100



GFAP

# Tumeurs du plexus choroïde: Diagnostics différentiels

- Hyperplasie villose
  - (Hydrocéphalie hypersécrétoire)
- Métastase:
  - Adénocarcinome: IHC: BerP4, CEA...

# Tumeurs du plexus choroïde: Traitement

- Chirurgical
- Survie à 5 ans : 80 %

**Fin de la Présentation**

**Merci de votre attention**